

足の診かた ver4-o, 2021.5  
西伊豆健育会病院 仲田和正

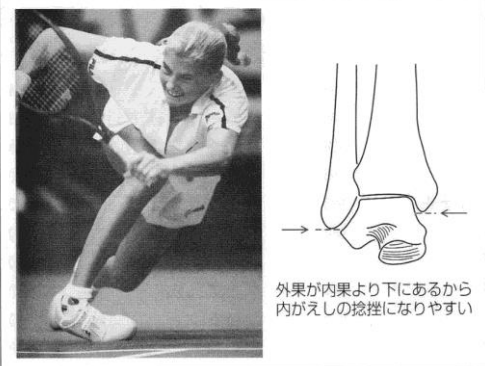
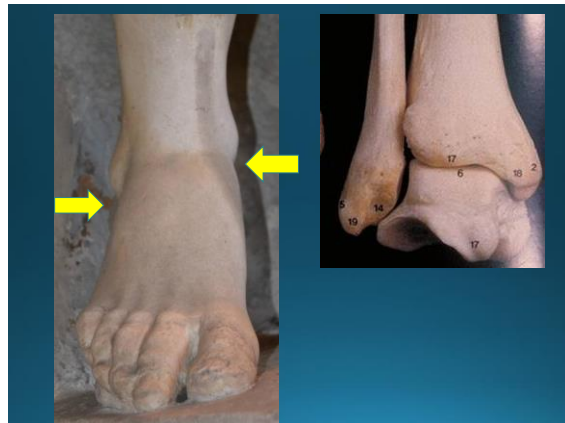


図1 内反捻挫の瞬間と足関節の仕組み

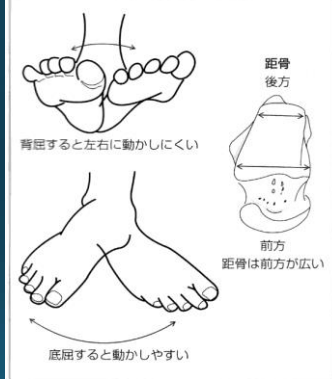
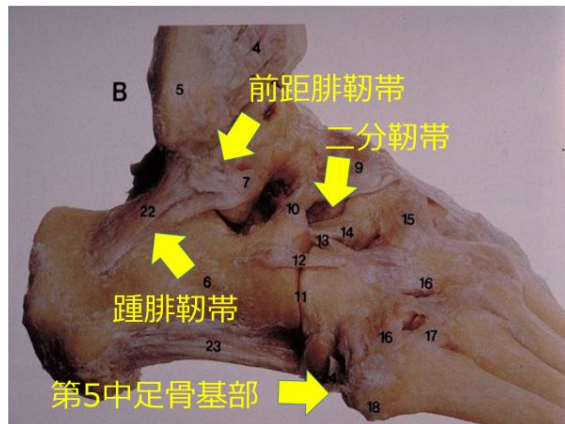

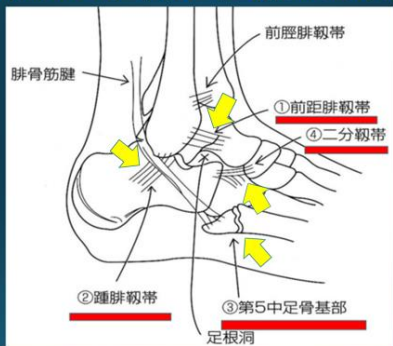


図2 足関節の動きと距骨

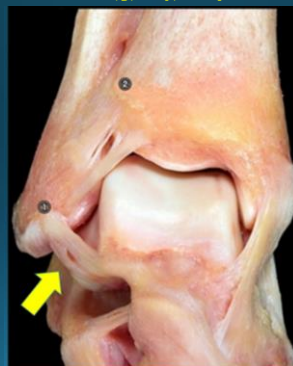
### 捻挫で外側の靭帯が切れやすい



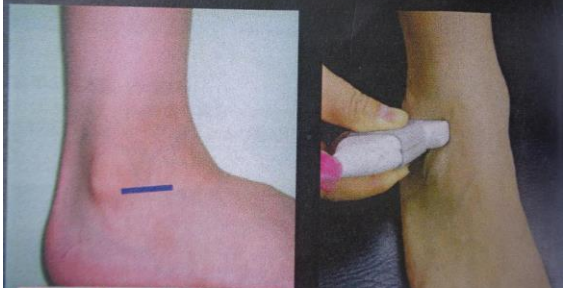
### 捻挫は4個所の圧痛を確認



### 前距腓靭帯

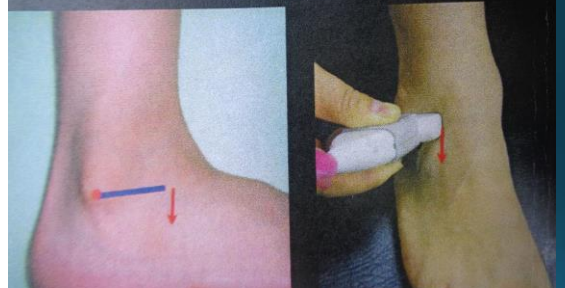


### プローブの位置



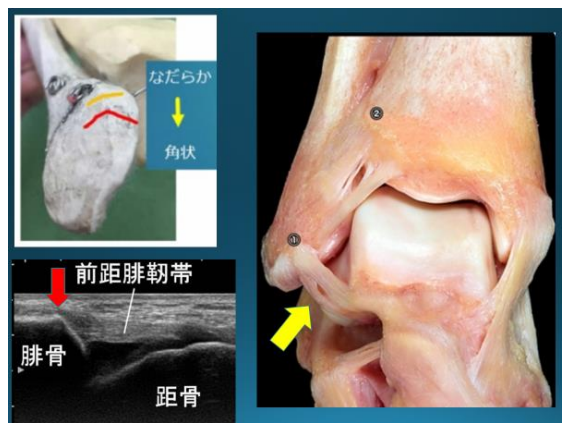
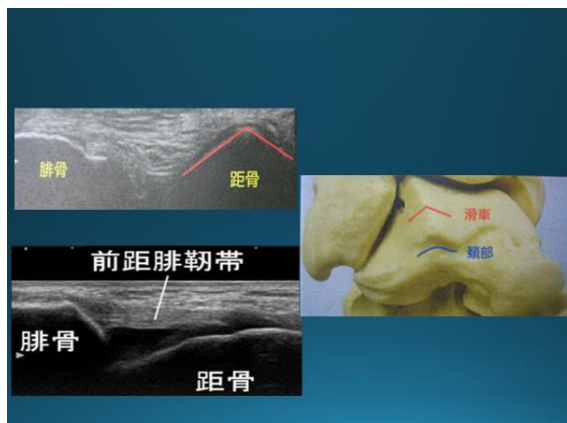
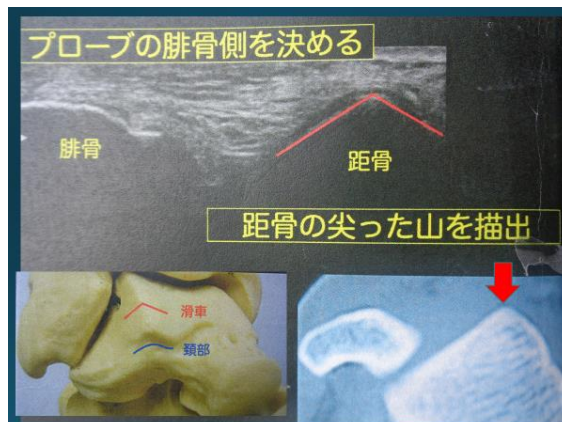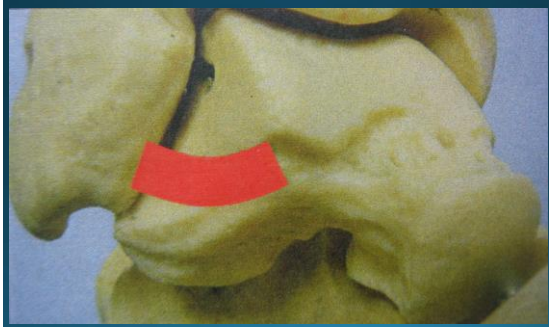
腓骨前下方斜面の遠位1/2に前方から！

### 距骨側を動かす

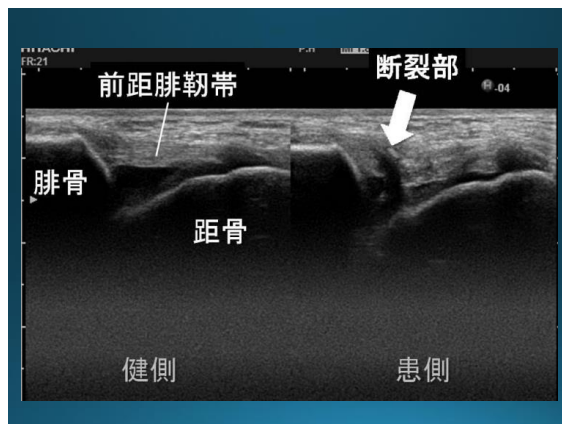
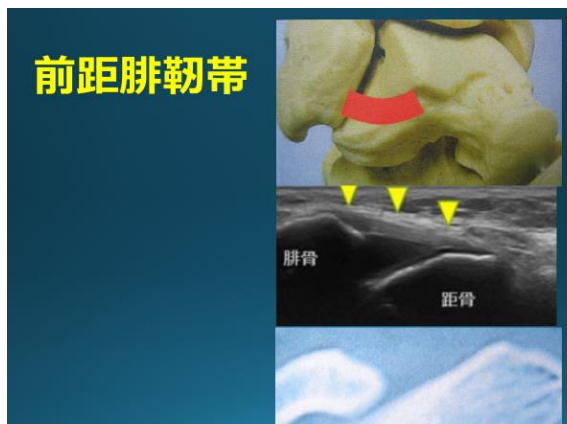


足底側に動かす！

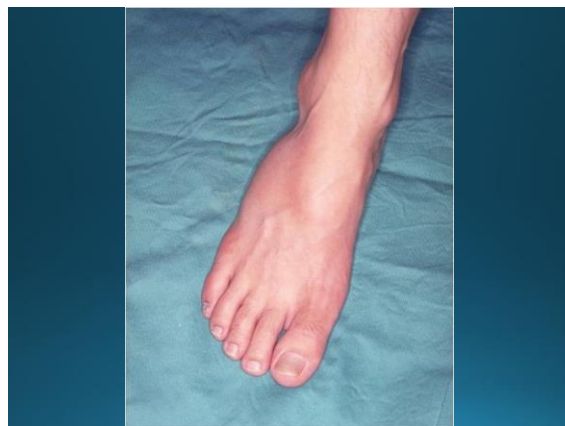
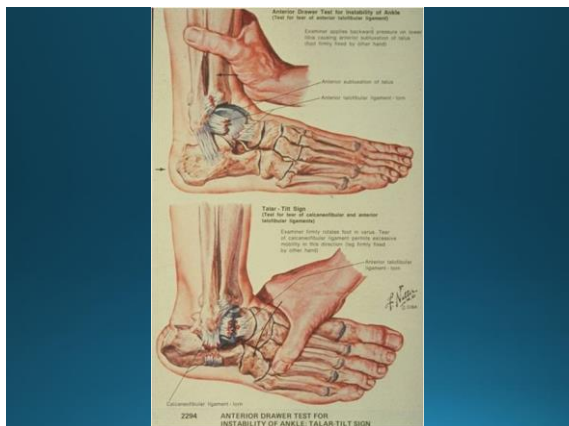
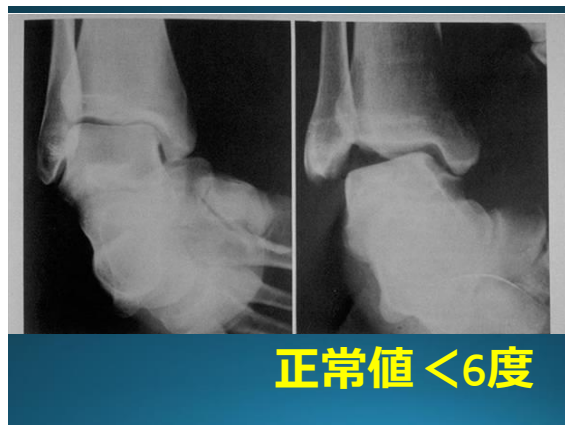
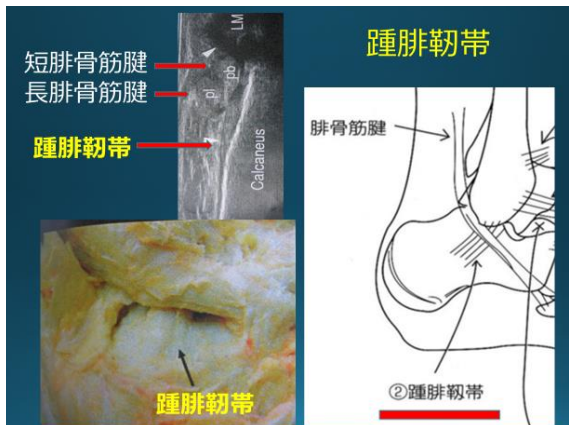
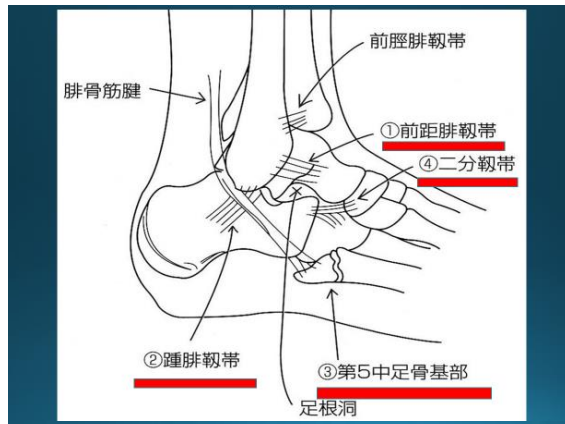
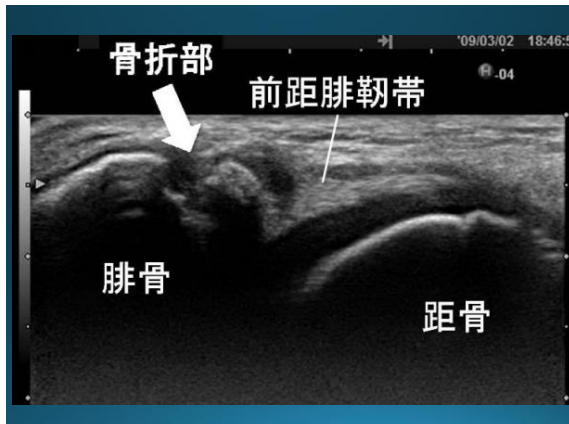# 前距腓靱帯の位置


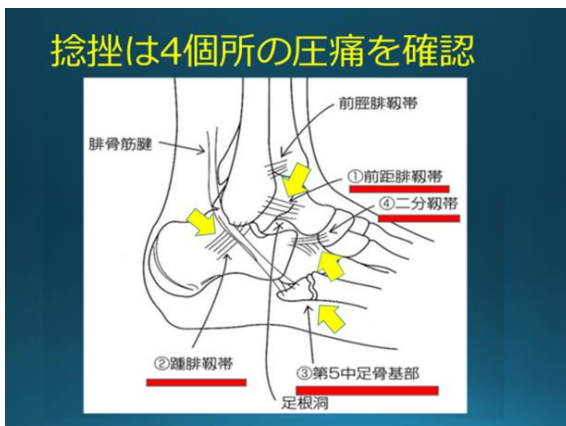
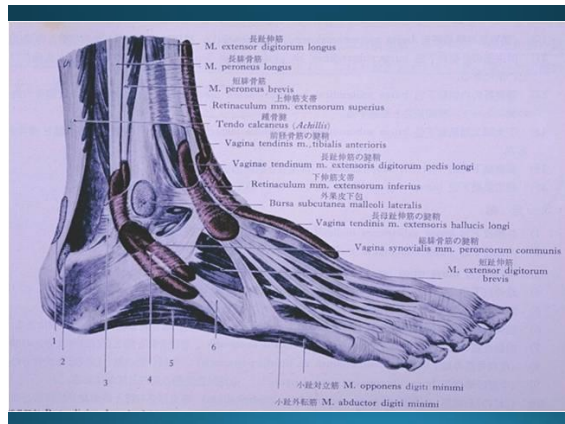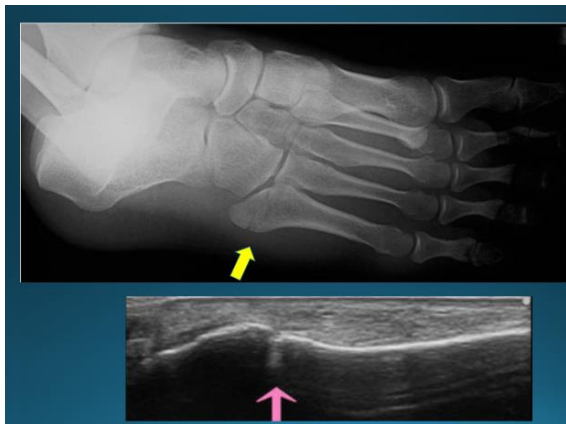


# 前距腓靱帯

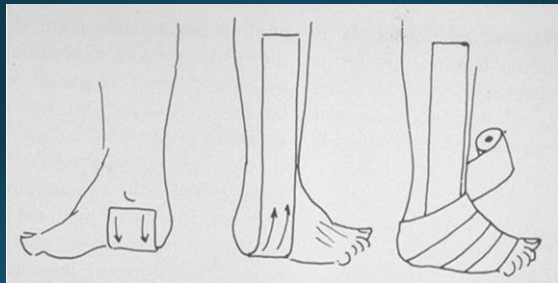




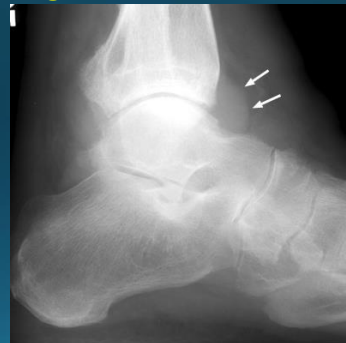



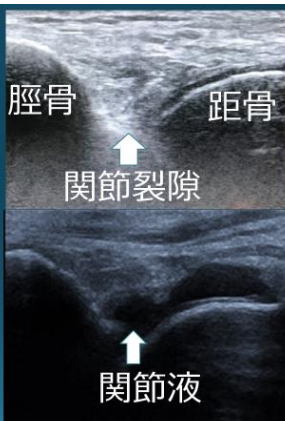
テーピング：内返しにならぬように



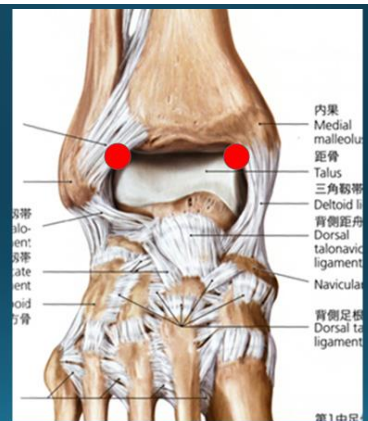
Tear drop sign



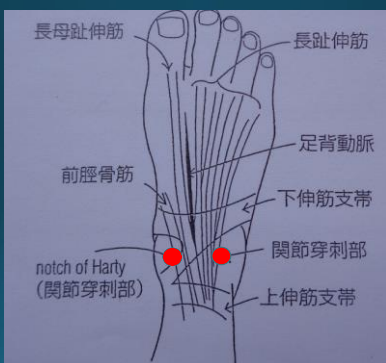足関節液



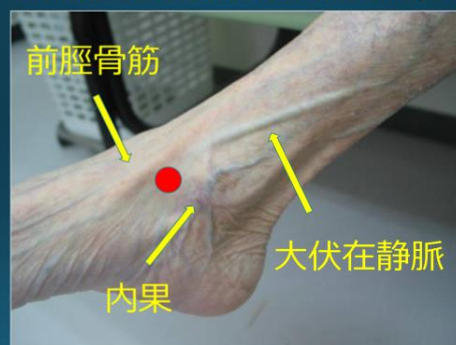
穿刺位置



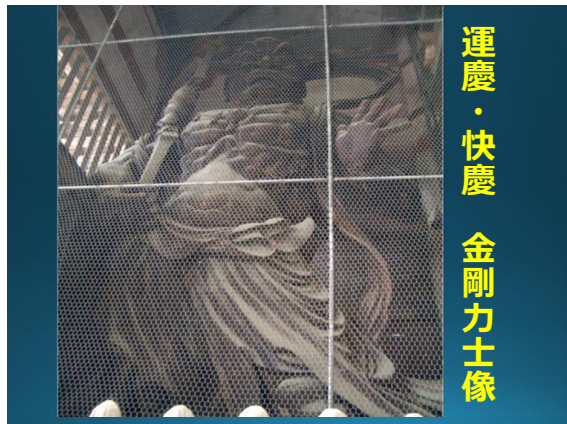関節穿刺の場所



足関節穿刺はnotch of Hartyに







運慶・快慶  
金剛力士像



天の原ふりさけみれば春日なる  
三笠の山にいでし月かも


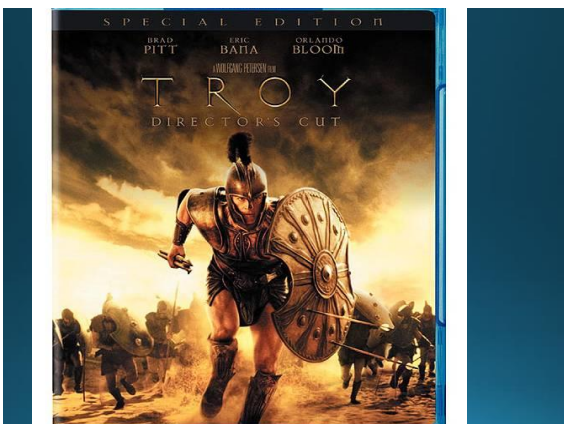

阿倍仲麻呂



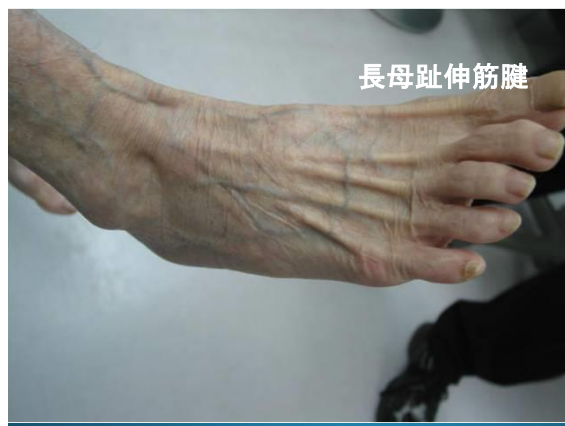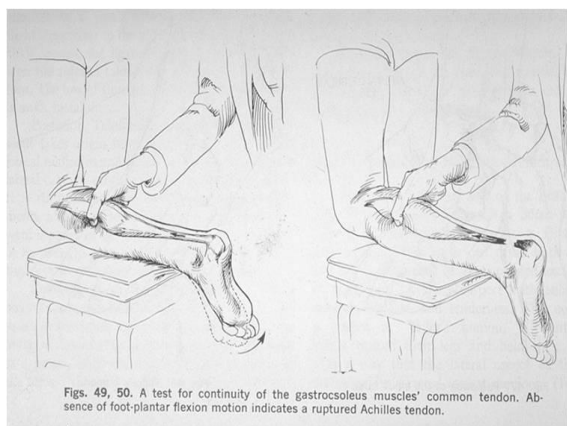
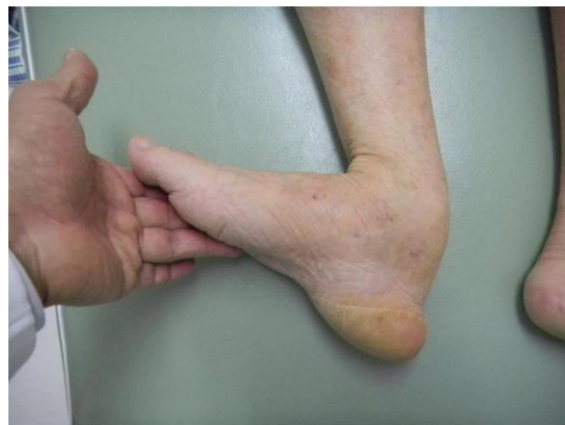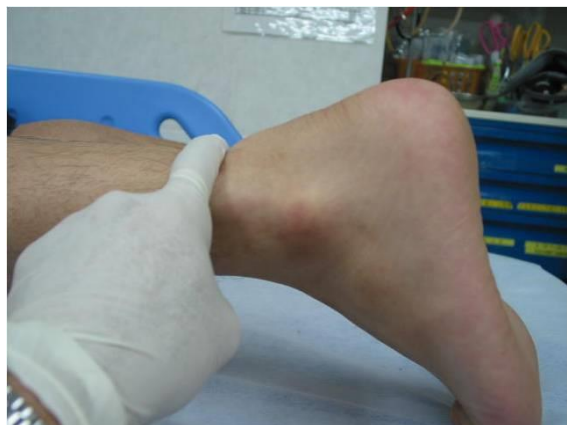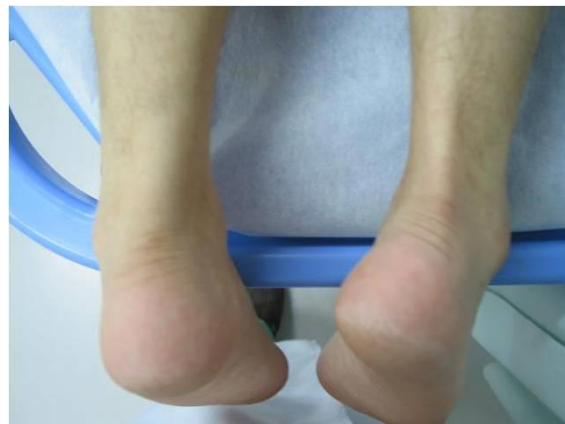
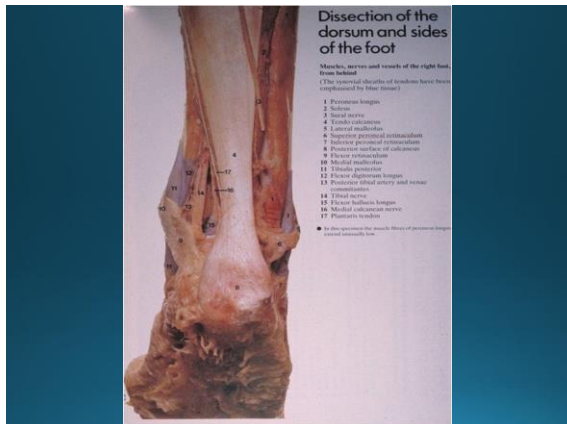
長安(西安)阿房宮

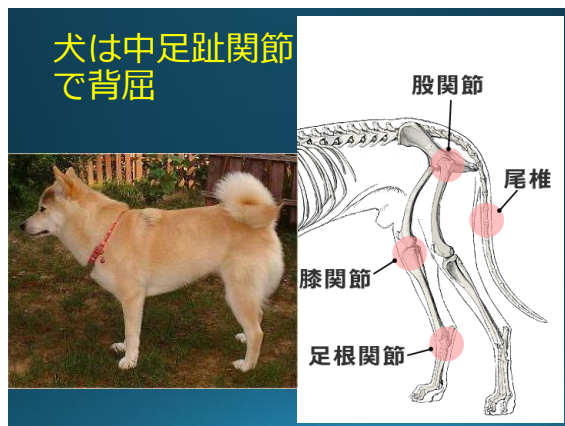
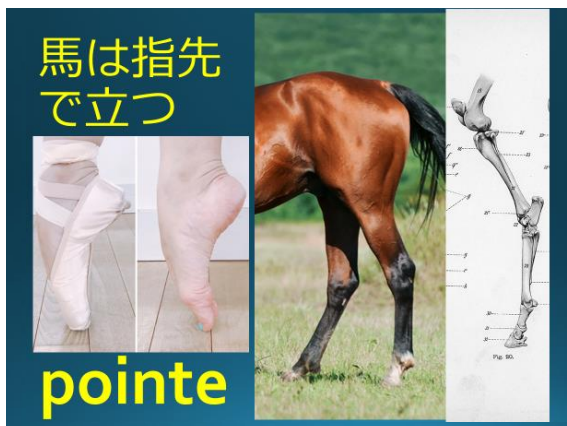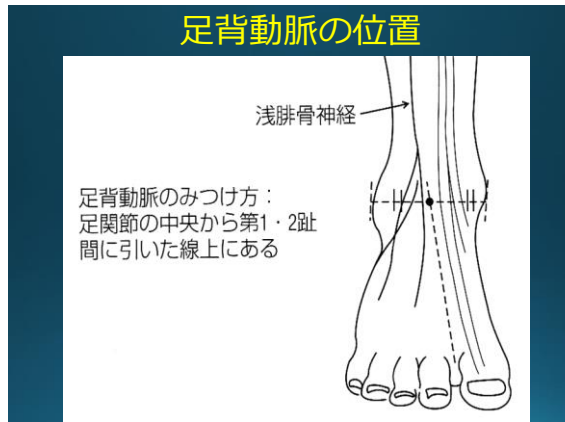

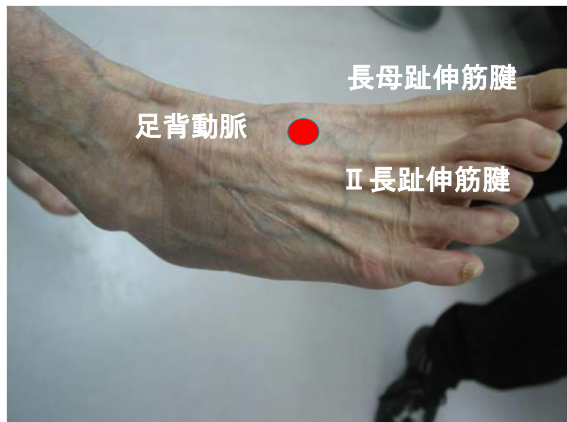
兵馬俑の靴底







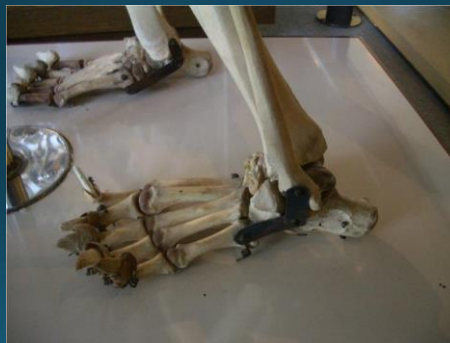



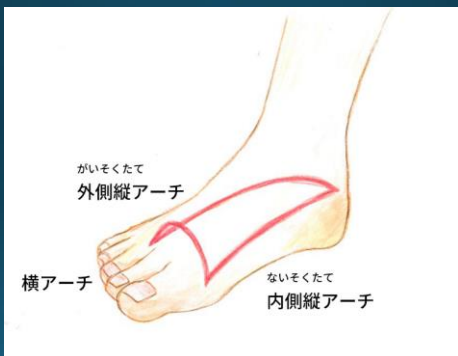### 熊はヒトと同じ立ち方



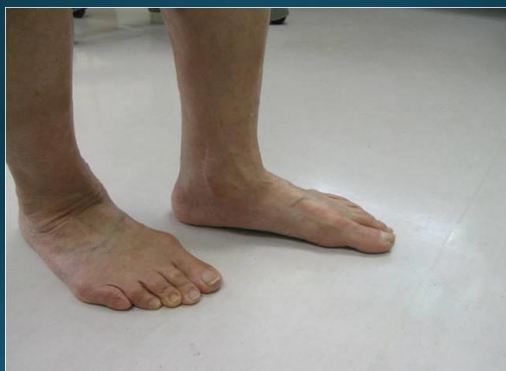### 登別クマ牧場



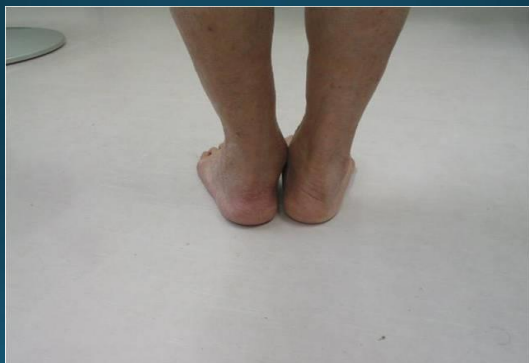### 足には縦アーチと横アーチあり



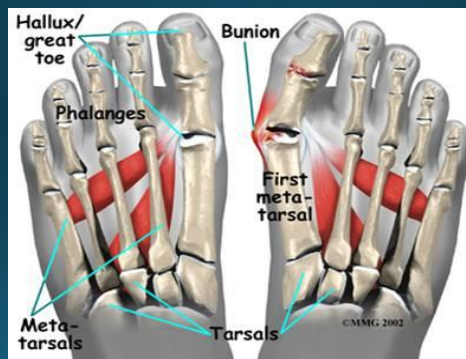### 扁平足 (Pes planus)

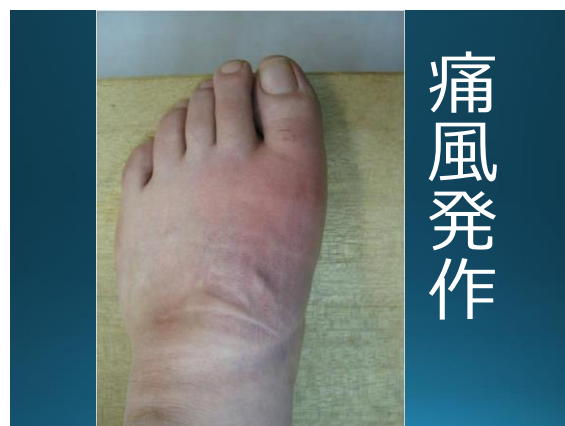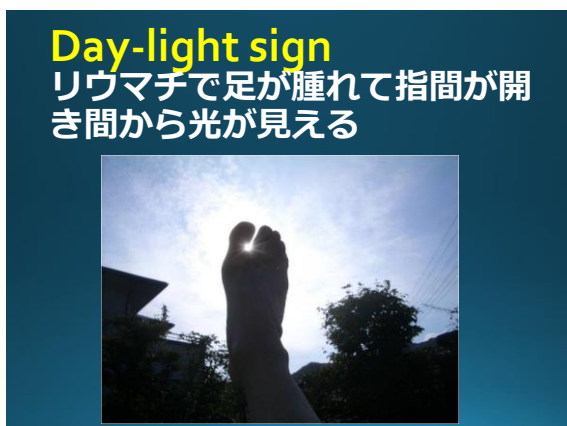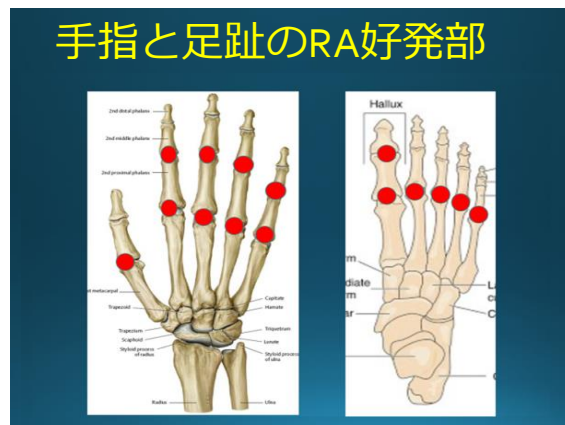
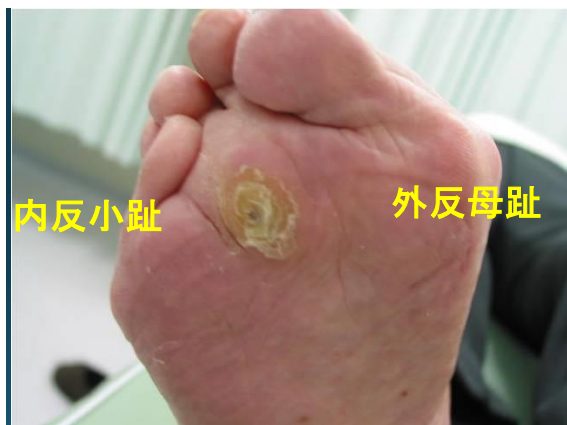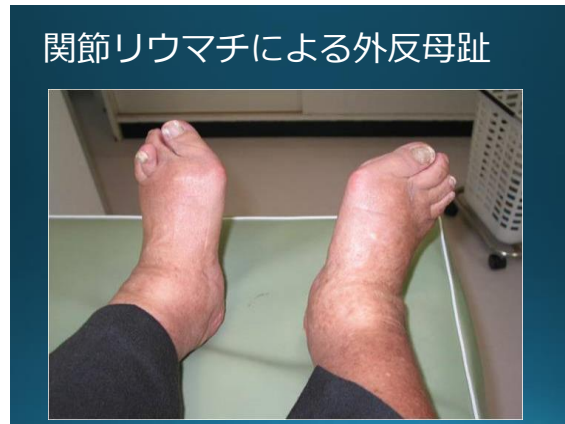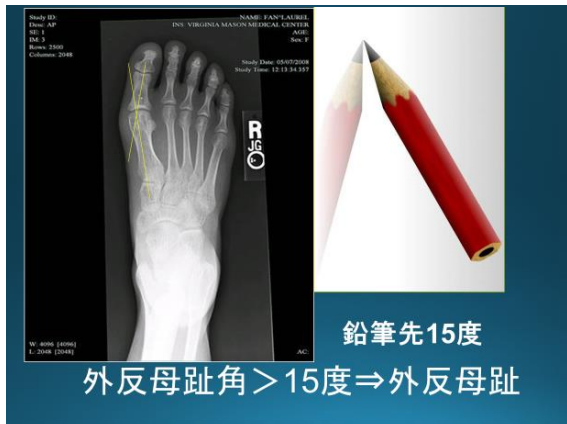


### Too-many-toes sign

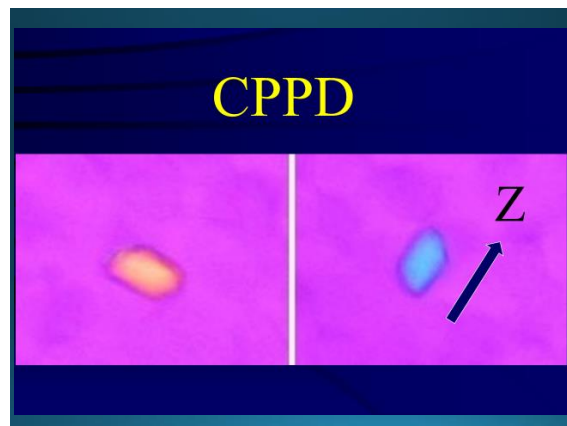
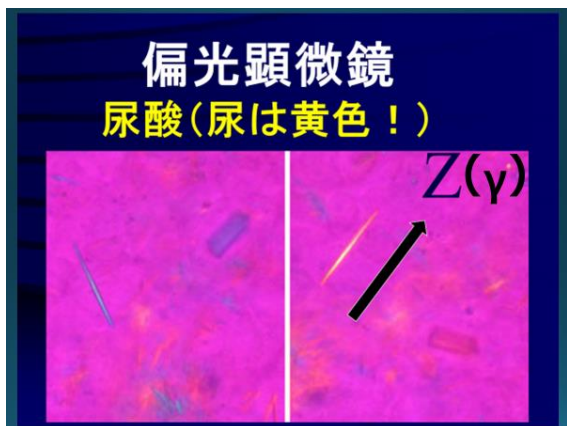
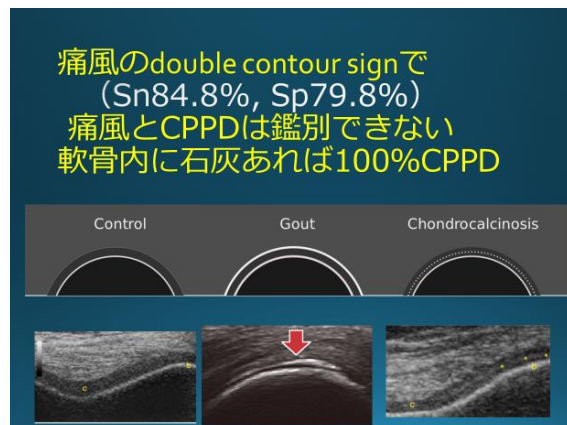
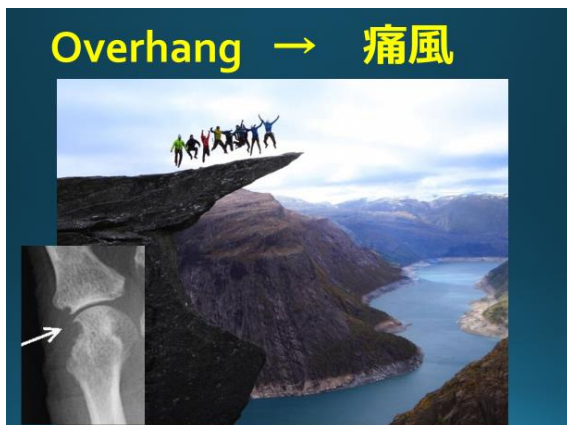
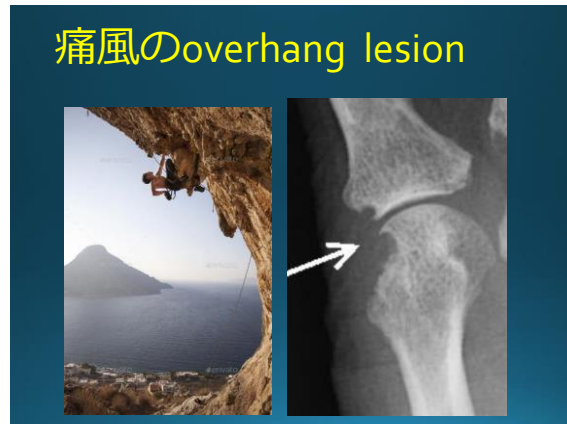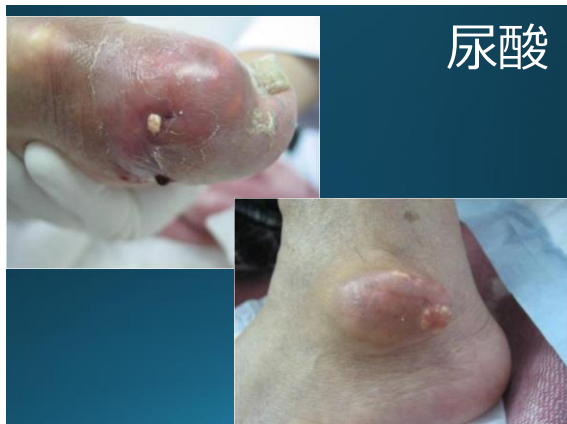### 横アーチ崩れ母趾内転筋で基節骨外反










偏光顕微鏡  
尿酸(尿は黄色!)



ご清聴ありがとうございました

